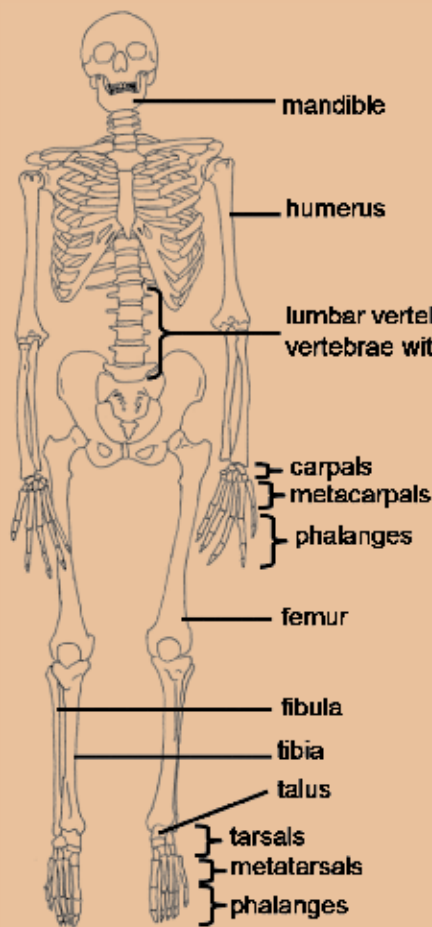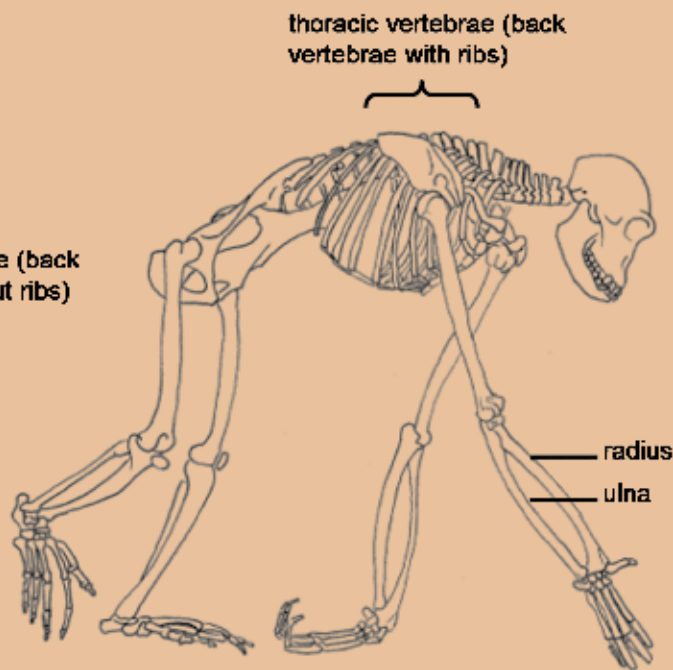
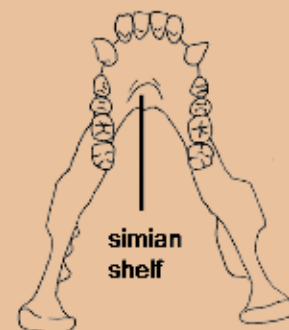


Human skeleton

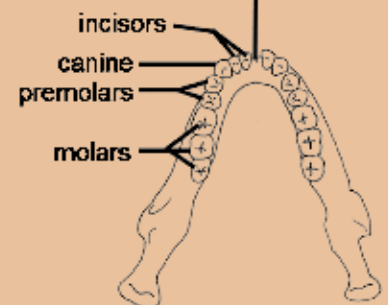


Chimp skeleton

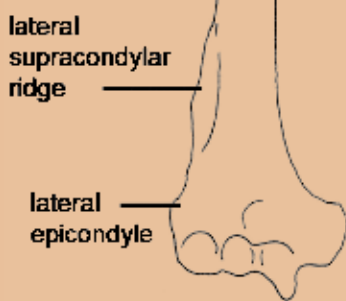


Chimp mandible

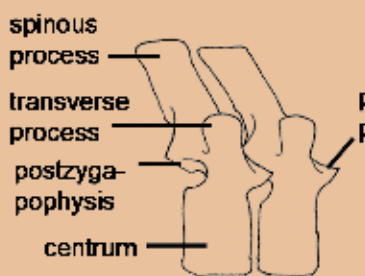
mandibular symphysis (line along which left and right halves of mandible fuse together during development)



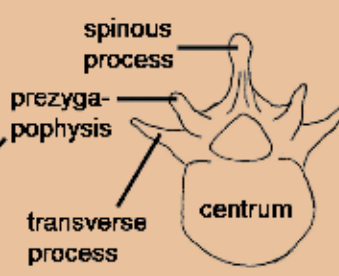
Human mandible



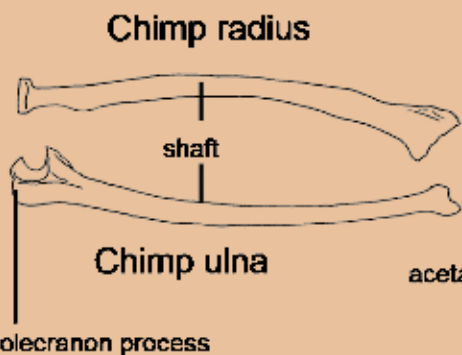
Chimp humerus



Chimp thoracic vertebrae



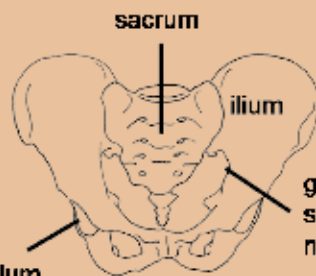
Chimp lumbar vertebra



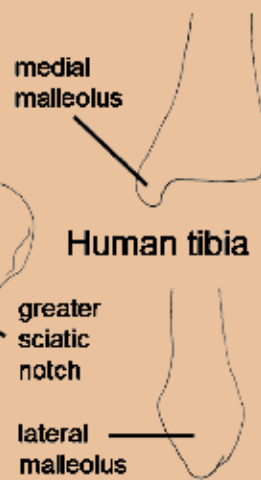
Chimp radius

Chimp ulna

acetabulum



Human pelvis



Human tibia

Human fibula